

# Use of cell-free collagen type I matrix implants for the treatment of small cartilage defects in the knee: clinical and magnetic resonance imaging evaluation

Karl F. Schüttler · Hanno Schenker · Christina Theisen · Markus D. Schofer · Alan Getgood · Philip P. Roessler · Johannes Struwer · Marga B. Rominger · Turgay Efe

Received: 24 June 2013 / Accepted: 23 October 2013  
© Springer-Verlag Berlin Heidelberg 2013

## Abstract

**Purpose** Articular cartilage defects of the knee are a common condition for which several repair techniques have been described. The aim of the present study was to assess medium-term results of a one-step procedure using a cell-free collagen type I matrix.

**Methods** Fifteen patients with articular cartilage defects of the knee were treated with an 11-mm-diameter cell-free collagen type I matrix implant. The matrices were implanted in a press-fit manner into the defect after careful debridement down to the subchondral bone but without penetration of this margin. Follow-up examinations were carried out at 6 weeks, 6 months, and at 12, 24, 36, and 48 months after implantation. Clinical assessment included the visual analogue scale (VAS), the Tegner activity scale, and the International Knee Documentation Committee (IKDC) score. Radiological assessment for graft attachment and tissue regeneration was performed using the magnetic observation of cartilage repair tissue (MOCART) score.

**Results** A total of 15 patients (males:  $n = 6$  and females:  $n = 9$ ) with a mean age of 26.4 years (range 19–40) were treated. The mean VAS improved significantly when compared to the preoperative values ( $P < 0.05$ ). Six weeks after implantation, IKDC values were slightly lower than the preoperative values (n.s.), but increased significantly at final follow-up ( $P < 0.05$ ). At 24 months, there were no significant differences in the median Tegner score between the post-operative values and the preoperative values (n.s.). However, after 36 months, a significant improvement was noted that lasted at least up to 48 months ( $P < 0.05$ ). The MOCART score improved consistently up to 4 years after implantation, with significant improvements already observed after 12 months ( $P < 0.05$ ). No correlation between the clinical scores and the MOCART score could be perceived.

**Conclusion** The present study showed that the use of cell-free collagen type I matrix implants led to a significant and durable improvement in all the clinical and imaging scores investigated 4 years after implantation.

**Level of evidence** IV.

K. F. Schüttler · H. Schenker · C. Theisen ·  
M. D. Schofer · P. P. Roessler · J. Struwer · T. Efe (✉)  
Department of Orthopaedics and Rheumatology, University  
Hospital Marburg, Baldingerstrasse, 35043 Marburg, Germany  
e-mail: efet@med.uni-marburg.de

C. Theisen  
Department of Trauma, Hand and Reconstructive Surgery,  
Wilhelms University Münster, Münster, Germany

A. Getgood  
Fowler Kennedy Sport Medicine Clinic, University of Western  
Ontario, London, ON, Canada

M. B. Rominger  
Department of Radiology, University Hospital Marburg,  
Marburg, Germany

**Keywords** Cartilage repair · MRI · Clinical  
outcome · Midterm results · Cell-free collagen type I

## Introduction

Several approaches are described in the current literature for the repair of articular cartilage defects, including bone marrow stimulation via microfracture or drilling, osteochondral transfer or autologous chondrocyte implantation (ACI) [2, 10, 14]. Despite the good clinical results that can be achieved by means of ACI in up to 70 % of patients on long-term follow-up, some inherent problems remain

unsolved [11, 20]. The surgical procedure for ACI is a two-step process requiring a first intervention to harvest chondrocytes and a second intervention to implant the cultured chondrocytes. A second problem is that the periosteal flaps, which were originally used to cover the defects to prevent leakage of the cellular suspension, can cause transplant hypertrophy or calcification [1, 25]. In recent years, tissue engineering has provided scaffolds or matrices seeded with chondrocytes—so-called matrix-induced autologous chondrocyte implantation—to help overcome these problems. Despite the promising results obtained in animal models [3, 24, 30] and clinical trials [17, 28], this technique has two disadvantages: it is a time-consuming technique that necessitates a second surgical procedure in order to implant the matrix incorporating the cultured chondrocytes, and it involves the risk of potential donor-site morbidity as a result of chondrocyte harvesting [16, 22]. In order to overcome these problems, one-step procedures have been introduced using the former matrices in a stand-alone, cell-free manner to serve as a carrier for chondrocytes to colonize the defect in vivo. Schneider et al. showed in an animal model that the use of a cell-free collagen type I scaffold led to high-quality repair tissue equal to the repair tissue formed after implantation of a cell-seeded scaffold in defects up to 12 mm in diameter [7, 24]. Short-term data for this new technique using a cell-free collagen type I matrix (CaReS-1S<sup>®</sup>, Arthro Kinetics, Krems/Donau, Austria) in human subjects have already been published and showed promising results [5]. However, the deterioration of clinical results due to inferior biomechanical properties of the repair tissue is a known problem of cartilage repair techniques, with midterm results often differing significantly from short-term data; therefore, longer follow-up periods are needed. No midterm results for this new cell-free scaffold are currently available. Therefore, the aim of this study was to evaluate the midterm results of a cell-free one-step repair technique for articular cartilage defects of the knee using a cell-free collagen type I matrix.

## Materials and methods

This study represents a prospective case series of patients recruited from the Department of Orthopaedics and Rheumatology of the University Hospital Marburg, from which short-term results were previously published [5]. All patients gave written informed consent before being included in the study. All patients included in this study failed conservative treatment represented by ongoing moderate pain limiting their sportive or recreation abilities as well as their quality of life and thus necessitating surgical intervention. Inclusion criteria were as follows: age between 18 and 50 years, symptomatic articular cartilage

**Table 1** Demographic data of the study population

Patients	<i>n</i>	15
Gender	Male	6
	Female	9
Age (years)	Mean	26.4
	SD	8.0
BMI (kg/m <sup>2</sup> )	Mean	25.4
	SD	5.1
	MFC	8
Localisation	LFC	3
	RP	4
	Aseptic necrosis	4
Diagnosis	Traumatic	8
	Idiopathic	3

*MFC* Medial femoral condyle, *LFC* Lateral femoral condyle, *RP* Retropatellar

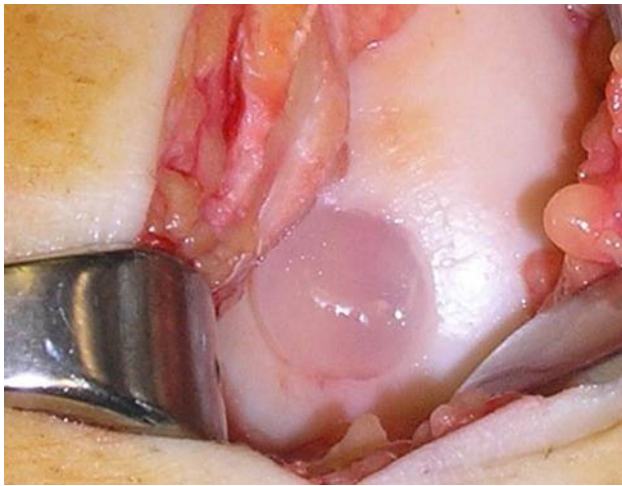
defects of International Cartilage Repair Society (ICRS, [2]) grades III and IV, and a defect size <11 mm in diameter. Exclusion criteria included ligamentous instability, meniscal defects with the loss of one-third or more of the meniscus, knee joint malalignment, inflammatory disease, ‘kissing lesions’, and articular cartilage degeneration in other joint compartments. Patients were scored preoperatively, 6 weeks after implantation, and 6, 12, 24, 36, and 48 months post-operatively using the subjective International Knee Documentation Committee (IKDC) score [12], the visual analogue score (VAS) for pain [6], and the Tegner activity scale [27].

MR imaging was performed using a 1.5-Tesla Magnetom Espree MRI Scanner (Siemens, Erlangen, Germany) as previously described [5]. All MR images were assessed by a senior musculoskeletal radiologist and graded using the MOCART score [18].

Patient demographics are shown in Table 1. Fifteen patients (males:  $n = 6$  and females:  $n = 9$ ) with a mean age of 26.4 years (range 19–40) were included. The right knee was involved in ten patients and the left in five. The chondral defects were localized on the medial femoral condyle in 8 patients (7 central/central; 1 central/posterior), the lateral femoral condyle in 3 (3 central/central), and the retropatellar surface in 4 (3 medial/central; 1 medial/distal) cases.

## Surgical procedure

Diagnostic arthroscopy was performed to evaluate the chondral lesion in vivo and to verify that the patient met the inclusion criteria. After verification, a mini-arthrotomy over the defect was performed to expose the specific compartment. In order to treat the defects localized on the



**Fig. 1** Intraoperative situs after implantation of the cell-free collagen type I matrix

retropatellar surface, the incision had to be slightly larger. Using an 11-mm-diameter cutter, the defect was punched out and debrided with an angulated curette down to the subchondral bone. Penetration of the subchondral bone layer was avoided in all cases. In the four patients that had suffered from osteonecrosis of the subchondral bone, a deep debridement of the sclerotic bone had to be performed. The resulting defect was filled with autologous cancellous bone from the proximal tibia. After debridement, the cell-free collagen type I matrices were directly implanted into the defects in a press-fit manner without any additional fixation (Fig. 1). The matrices used (CaReS-1S<sup>®</sup>, Arthro Kinetics, Krems/Donau, Austria), and the surgical procedure has already been described in detail within the publication presenting the short-term results [5].

For the four defects localized on the retropatellar surface, an 11 × 6 mm graft was used to account for the greater thickness of the articular cartilage in this compartment compared to that of the femoral condyle where 11 × 4 mm grafts were used. Post-operative rehabilitation included toe-touch weight-bearing for 4 weeks and limitation of flexion to 0° for 2 days followed by 30° for the next 3 weeks. Full flexion and weight-bearing were achieved within the fourth to sixth week.

The study was performed in accordance with the Declaration of Helsinki and was authorized by the local research and ethics committee (study no. 42/08).

#### Statistical analysis

For a sample size of 15 patients, descriptive statistical methods were used in the analysis of this study. For quantitative variables, means and medians as well as standard deviations and interquartile ranges were calculated as measures of location and dispersion, respectively.

For qualitative variables, corresponding absolute and relative frequencies were determined. To identify any relationships between the variables of the MOCART score and the clinical scores (IKDC, VAS, Tegner) at different follow-up times, the Pearson's product moment correlation was performed. Paired *t* tests with a significance level of 5 % as well as determination of the 95 % confidence interval were performed for clinical scores (IKDC, VAS) and the MOCART score to compare pre- and post-operative values. For the Tegner activity scale, the nonparametric Wilcoxon test with a significance level of 5 % was used. To avoid negative values, differences in the mean for IKDC were calculated as post-operative–preoperative. For VAS, the difference in the mean was calculated as preoperative–post-operative.

#### Results

All fifteen patients completed the clinical and magnetic resonance imaging follow-up at 48 months. The mean defect size was  $0.82 \pm 0.19 \text{ cm}^2$  (range 0.55–1.0). No complications related to surgery or graft fixation were observed.

#### Clinical outcome

Confidence intervals and *p* values for all clinical scores at all points of follow-up are given in Table 2. All clinical values improved significantly compared to preoperative status. The mean VAS improved from 4.6 preoperatively to 2.2 at final follow-up ( $P < 0.05$ ). Six weeks after implantation, the IKDC values were slightly lower than the preoperative values (n.s.), but increased significantly afterwards and up to 48 months post-operatively ( $P < 0.05$ ).

Up to 24 months, there were no significant differences in the median Tegner score between the post-operative values and the preoperative values. Only after 36 months was a significant improvement from the baseline observed ( $P < 0.05$ ). This significant improvement lasted at least up to 48 months ( $P < 0.05$ ); although when compared to the value at 36 months after implantation, a slight deterioration of the activity level could be seen, represented by a decrease in the median Tegner score from 5.0 (range 3–9) at 36 months to 4.0 (range 2–9) at 48 months. Nevertheless, patients were able to participate in recreational sports and perform moderately heavy labour at the latest follow-up.

#### Magnetic resonance imaging outcome

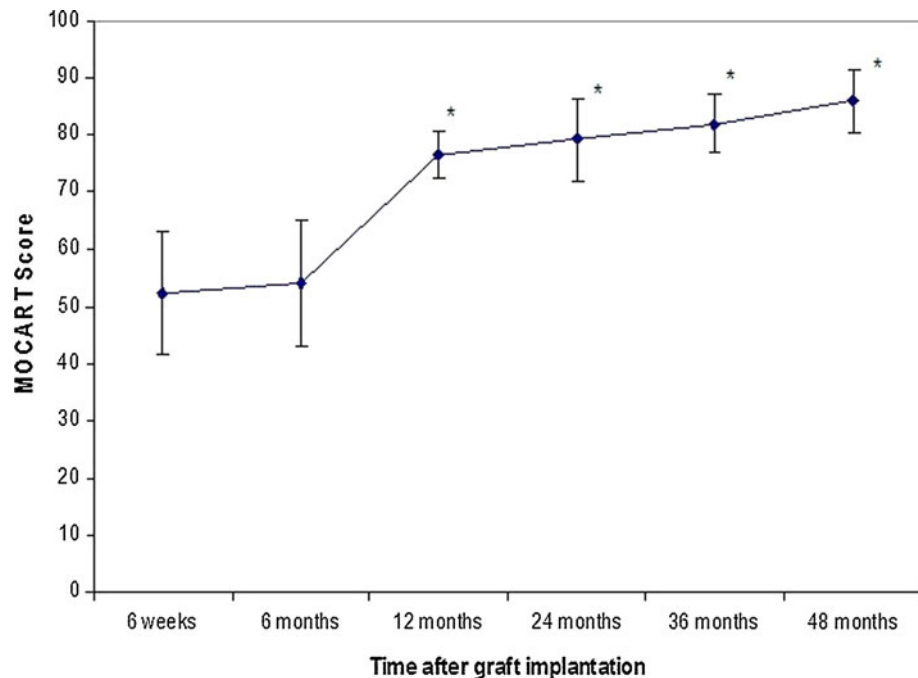
The MOCART score improved continually up to 48 months after implantation and already showed significant improvements after 12 months ( $P < 0.05$ ); Fig. 2). At

**Table 2** Results of the clinical scores (IKDC, VAS) given as differences of the mean with the 95 % confidence interval and the associated *p* values

	Preop. versus 6 weeks	Preop. versus 6 months	Preop. versus 12 months	Preop. versus 24 months	Preop. versus 36 months	Preop. versus 48 months
<i>IKDC</i>						
Difference of the mean	2.14	24.79	22.83	23.67	26.51	28.99
95 % CI	-8.49-12.78	12.30-37.28	8.81-36.85	7.00-40.35	13.73-39.29	17.09-40.89
<i>p</i> value	n.s.	0.0009	0.0036	0.0087	0.0005	0.0001
<i>VAS</i>						
Difference of the mean	2.60	2.35	2.66	2.60	2.46	2.40
95 % CI	0.94-4.25	0.89-3.81	1.06-4.26	0.88-4.31	1.14-3.78	1.16-3.63
<i>p</i> value	0.0047	0.0040	0.0031	0.0057	0.0013	0.0009
<i>Tegner</i>						
Median	2.5 versus 2.0	2.5 versus 4.0	2.5 versus 3.0	2.5 versus 4.0	2.5 versus 5.0	2.5 versus 4.0
Range	(0-9) (0-3)	(0-9) (1-6)	(0-9) (1-6)	(0-9) (1-7)	(0-9) (3-9)	(0-9) (2-9)
<i>p</i> value	n.s.	n.s.	n.s.	n.s.	0.0098	0.0232

Results for Tegner activity scale are given as median, range and associated *p* values

**Fig. 2** Mean and standard deviation of the magnetic observation of cartilage repair tissue (MOCART) score. The asterisks indicate a statistically significant difference ( $P < 0.05$ ) compared with the MOCART score 6 weeks post-operatively



the latest follow-up, all defects were filled and complete integration of the matrices into the border zone was seen in all fifteen patients. The repair tissue had changed its signal intensity to almost normal in several cases (Fig. 3). Correlation analysis showed no linear correlation between the clinical scores and the MOCART score.

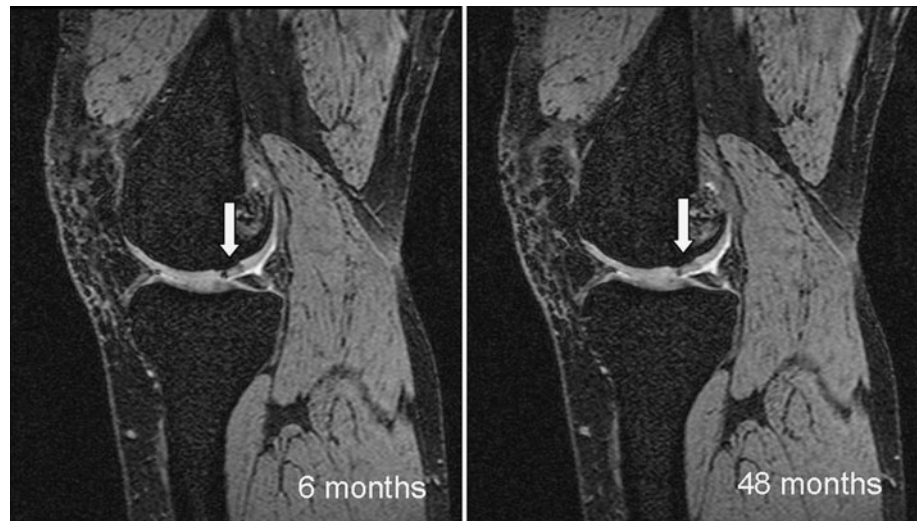
## Discussion

The most important finding of the present study was that the implantation of a cell-free collagen type I matrix leads

to favourable and durable clinical results, with the formation of repair tissue, as shown by the magnetic resonance evaluation at midterm follow-up.

The importance of mid- to long-term results of cartilage repair techniques is underlined when considering the deterioration of initially good to excellent clinical results after mid- to long-term follow-up due to inferior quality of the repair tissue formed as a result of procedures such as microfracture [8, 15]. The formation and quality of repair tissue after implantation of cell-free matrices has been evaluated in several experimental studies using different animal models. Schneider et al. [24] compared a cell-based

**Fig. 3** Magnetic resonance images of a 23-year-old male patient. The graft in the medial femoral condyle (*white arrow*) is completely attached with intact surface after 6 months post-operatively. At 48 months, the structure and the signal intensity show some alterations



procedure (MACI) with the same scaffold used in this present study in a Goettinger minipig model, resulting in high-quality repair tissue that, after one year, was equal to the tissue achieved using the cell-based technique. Gavenis et al. [7] investigated a cell-free collagen type 1 matrix in vitro and in a nude-mouse model, and showed in both scenarios that the cell-free scaffold offered an environment that allowed colonization by chondrocytes and subsequent transformation of the former matrix into repair tissue. Although the possibility of chondrocytes migrating and thus their potential to colonize the former cell-free matrix is acknowledged in the current literature, the underlying mechanism remains unclear [21, 24], while the source of such colonizing cells is also unknown. Possible origins are, for example, the surrounding articular cartilage or the synovial fluid.

The mean MOCART score in the present study was 86 after 48 months of follow-up, representing the formation of repair tissue with excellent morphological characteristics. Although no second-look arthroscopy or histological examination was performed to assess the quality of the repair tissue in this study, the evaluation of the repair tissue via the MOCART score showed excellent results and a further improvement when compared to the short-term results. Several studies have investigated the reliability of the MOCART score itself and shown excellent interobserver reliability and a good correlation with clinical results especially for the criteria ‘filling of the defect’, ‘structure of the repair tissue’, ‘changes in the subchondral bone’, and ‘signal intensities of the repair issue’, thus making high-resolution MRI a reliable, reproducible, and accurate tool for assessing cartilage repair tissue non-invasively [13, 18].

Although good correlations between MOCART score and clinical outcome have been described in the current literature, no strong correlation could be perceived in the present study. This may be due to the relatively small

sample size and the fact that multiple possible correlations were investigated.

Importantly, the MRI evaluation in the present study was able to show a positive integration of the scaffold into the border zone with a consistent improvement in the MOCART score over time for every patient. Furthermore, in every patient, progression from incomplete filling of the defect at 6 months post-operatively towards complete filling at the latest follow-up was observed, as well as a trend towards the normalization of the signal intensity of the repair tissue and its integration into the border zone. This may represent the desired implant in-growth with colonization by chondrocytes or other cell type from the host, resulting in the transformation of the scaffold.

With regard to the current literature, there is potential evidence from a biomechanic study that defects smaller than 8 mm do not increase the rim stress of the perilesional cartilage tissue [9]. Only cartilage defects >10 mm showed evidence for increased rim stress and altered load distribution thus potentially enlarging defect size resulting in secondary osteoarthritis. Therefore, surgical treatment for defects below this margin of 8 mm is critical with regard to this biomechanical view. Nevertheless, definitive decision must consider the multifactorial origin of osteoarthritis and as all patients included in this study presented with symptomatic defects impairing their quality of life surgical treatment was indicated.

Comparison with alternative surgical techniques for cartilage repair is difficult and susceptible to bias as this study was performed without a control group and thus comparison has to be made with the results reported in the literature. For small articular cartilage defects, the gold standard repair technique remains the microfracture procedure. Steadman et al. [26] were able to show satisfactory results at an average of 11 years after microfracture in patients aged 45 years and younger with a mean Tegner

score of 6 at the latest follow-up. Unfortunately, no MRI was performed in their study. Marquass et al. [19] reported a mean MOCART scores of  $41.2 \pm 7.7$  and  $39.4 \pm 16.1$  approximately 7 years after osteochondral transfer and microfracture, respectively, to treat cartilage defects of the medial femoral condyle. Dhollander et al. [4] reported a MOCART score of 67 (range 50–83) 2 years after microfracture in combination with a cell-free polymer-based implant impregnated with autologous serum for cartilage defects. Welsch et al. [29] compared the microfracture procedure with MACI in twenty patients up to 63 months post-operatively and reported a MOCART score of  $75.5 \pm 13.0$  (range 50–90) after MACI and  $75.0 \pm 12.0$  (range 50–90) after microfracturing. All authors reported a good clinical outcome independent of the method of surgery.

The mean MOCART score of 86 in the present study represents a comparable, if not better appearance of the repair tissue, thus raising the hope that in addition to the favourable MR outcome, the favourable clinical improvement observed in this study might last for long-term intervals.

Comparison of the present data with the results of Schneider et al. [23], who investigated a cell-based technique using the same collagen type I matrix in a multicentre study involving 116 patients with a mean follow-up of 30 months and found a mean IKDC of 70.5 and a mean VAS of 3.2 at the latest follow-up, shows similar results, thus underlining the ongoing trend towards cell-free repair techniques.

The present study has some limitations. Firstly, the treated defects were small in size and the study population was rather small. Secondly, no control group was included for direct comparison and thus comparison to other repair techniques had to be made by referring to the literature. Despite these limitations, the present study was able to show, both clinically and by means of magnetic resonance imaging, in a precisely defined population, that the promising short-term results reported for the use of cell-free collagen type I matrix for repair of articular cartilage defects did not deteriorate over time but continued to improve.

## Conclusion

The treatment for small full thickness articular cartilage defects with a cell-free type I collagen matrix provides durable clinical improvements in patient-reported outcome and tissue repair morphology, as assessed by MRI, at midterm follow-up.

**Conflict of interest** The magnetic resonance imaging was supported by a research fund of Arthro Kinetics.

## References

- Bartlett W, Skinner JA, Gooding CR, Carrington RW, Flanagan AM, Briggs TW, Bentley G (2005) Autologous chondrocyte implantation versus matrix-induced autologous chondrocyte implantation for osteochondral defects of the knee: a prospective, randomised study. *J Bone Joint Surg Br* 87:640–645
- Brittberg M, Winalski CS (2003) Evaluation of cartilage injuries and repair. *J Bone Joint Surg* 85-A(Suppl 2):58–69
- Christensen BB, Foldager CB, Hansen OM, Kristiansen AA, Le DQ, Nielsen AD, Nygaard JV, Bunger CE, Lind M (2012) A novel nano-structured porous polycaprolactone scaffold improves hyaline cartilage repair in a rabbit model compared to a collagen type I/III scaffold: in vitro and in vivo studies. *Knee Surg Sports Traumatol Arthrosc* 20:1192–1204
- Dhollander AA, Verdonk PC, Lambrecht S, Almqvist KF, Elewaut D, Verbruggen G, Verdonk R (2011) The combination of microfracture and a cell-free polymer-based implant immersed with autologous serum for cartilage defect coverage. *Knee Surg Sports Traumatol Arthrosc* 20:1773–1780
- Efe T, Theisen C, Fuchs-Winkelmann S, Stein T, Getgood A, Rominger MB, Paletta JR, Schofer MD (2012) Cell-free collagen type I matrix for repair of cartilage defects-clinical and magnetic resonance imaging results. *Knee Surg Sports Traumatol Arthrosc* 20:1915–1922
- Flandry F, Hunt JP, Terry GC, Hughston JC (1991) Analysis of subjective knee complaints using visual analog scales. *Am J Sports Med* 19:112–118
- Gavenis K, Schneider U, Maus U, Mumme T, Muller-Rath R, Schmidt-Rohlfing B, Andereya S (2012) Cell-free repair of small cartilage defects in the Goettinger minipig: which defect size is possible? *Knee Surg Sports Traumatol Arthrosc* 20:2307–2314
- Gobbi A, Nunag P, Malinowski K (2005) Treatment of full thickness chondral lesions of the knee with microfracture in a group of athletes. *Knee Surg Sports Traumatol Arthrosc* 13:213–221
- Guettler JH, Demetropoulos CK, Yang KH, Jurist KA (2004) Osteochondral defects in the human knee: influence of defect size on cartilage rim stress and load redistribution to surrounding cartilage. *Am J Sports Med* 32:1451–1458
- Harris JD, Siston RA, Pan X, Flanigan DC (2010) Autologous chondrocyte implantation: a systematic review. *J Bone Joint Surg Am* 92:2220–2233
- Henderson I, Francisco R, Oakes B, Cameron J (2005) Autologous chondrocyte implantation for treatment of focal chondral defects of the knee—a clinical, arthroscopic, MRI and histologic evaluation at 2 years. *Knee* 12:209–216
- Irrgang JJ, Anderson AF, Boland AL, Harner CD, Kurosaka M, Neyret P, Richmond JC, Shelborne KD (2001) Development and validation of the international knee documentation committee subjective knee form. *Am J Sports Med* 29:600–613
- James SL, Connell DA, Saifuddin A, Skinner JA, Briggs TW (2006) MR imaging of autologous chondrocyte implantation of the knee. *Eur Radiol* 16:1022–1030
- Kalson NS, Gikas PD, Briggs TW (2010) Current strategies for knee cartilage repair. *Int J Clin Pract* 64:1444–1452
- Kreuz PC, Steinwachs MR, Erggelet C, Krause SJ, Konrad G, Uhl M, Sudkamp N (2006) Results after microfracture of full-thickness chondral defects in different compartments in the knee. *Osteoarthr Cartil* 14:1119–1125
- LaPrade RF, Botker JC (2004) Donor-site morbidity after osteochondral autograft transfer procedures. *Arthroscopy* 20:69–73
- Marlovits S, Aldrian S, Wondrasch B, Zak L, Albrecht C, Welsch G, Trattnig S (2012) Clinical and radiological outcomes 5 years

- after matrix-induced autologous chondrocyte implantation in patients with symptomatic, traumatic chondral defects. *Am J Sports Med* 40:2273–2280
18. Marlovits S, Singer P, Zeller P, Mandl I, Haller J, Trattnig S (2006) Magnetic resonance observation of cartilage repair tissue (MOCART) for the evaluation of autologous chondrocyte transplantation: determination of interobserver variability and correlation to clinical outcome after 2 years. *Eur J Radiol* 57:16–23
  19. Marquass B, Mahn T, Engel T, Gossner J, Theopold JD, von Dercks N, Racynski C, Rose T, Josten C, Hepp P (2012) Clinical and radiological mid-term results after autologous osteochondral transplantation under consideration of quality of life. *Z Orthop Unfall* 150:360–367
  20. Micheli LJ, Browne JE, Erggelet C, Fu F, Mandelbaum B, Moseley JB, Zurakowski D (2001) Autologous chondrocyte implantation of the knee: multicenter experience and minimum 3-year follow-up. *Clin J Sport Med* 11:223–228
  21. Morales TI (2007) Chondrocyte moves: clever strategies? *Osteoarthr Cartil* 15:861–871
  22. Niemeyer P, Pestka JM, Kreuz PC, Erggelet C, Schmal H, Suedkamp NP, Steinwachs M (2008) Characteristic complications after autologous chondrocyte implantation for cartilage defects of the knee joint. *Am J Sports Med* 36:2091–2099
  23. Schneider U, Rackwitz L, Andereya S, Siebenlist S, Fensky F, Reichert J, Loer I, Barthel T, Rudert M, Noth U (2011) A prospective multicenter study on the outcome of type I collagen hydrogel-based autologous chondrocyte implantation (CaReS) for the repair of articular cartilage defects in the knee. *Am J Sports Med* 39:2558–2565
  24. Schneider U, Schmidt-Rohlfing B, Gavenis K, Maus U, Mueller-Rath R, Andereya S (2011) A comparative study of 3 different cartilage repair techniques. *Knee Surg Sports Traumatol Arthrosc* 19:2145–2152
  25. Sohn DH, Lottman LM, Lum LY, Kim SG, Pedowitz RA, Coutts RD, Sah RL (2002) Effect of gravity on localization of chondrocytes implanted in cartilage defects. *Clin Orthop Relat Res* 394:254–262
  26. Steadman JR, Briggs KK, Rodrigo JJ, Kocher MS, Gill TJ, Rodkey WG (2003) Outcomes of microfracture for traumatic chondral defects of the knee: average 11-year follow-up. *Arthroscopy* 19:477–484
  27. Tegner Y, Lysholm J (1985) Rating systems in the evaluation of knee ligament injuries. *Clin Orthop Relat Res* 198:43–49
  28. Vijayan S, Bartlett W, Bentley G, Carrington RW, Skinner JA, Pollock RC, Alorjani M, Briggs TW (2012) Autologous chondrocyte implantation for osteochondral lesions in the knee using a bilayer collagen membrane and bone graft: a two- to eight-year follow-up study. *J Bone Joint Surg Br* 94:488–492
  29. Welsch GH, Trattnig S, Domayer S, Marlovits S, White LM, Mamisch TC (2009) Multimodal approach in the use of clinical scoring, morphological MRI and biochemical T2-mapping and diffusion-weighted imaging in their ability to assess differences between cartilage repair tissue after microfracture therapy and matrix-associated autologous chondrocyte transplantation: a pilot study. *Osteoarthr Cartil* 17:1219–1227
  30. Willers C, Chen J, Wood D, Xu J, Zheng MH (2005) Autologous chondrocyte implantation with collagen bioscaffold for the treatment of osteochondral defects in rabbits. *Tissue Eng* 11:1065–1076